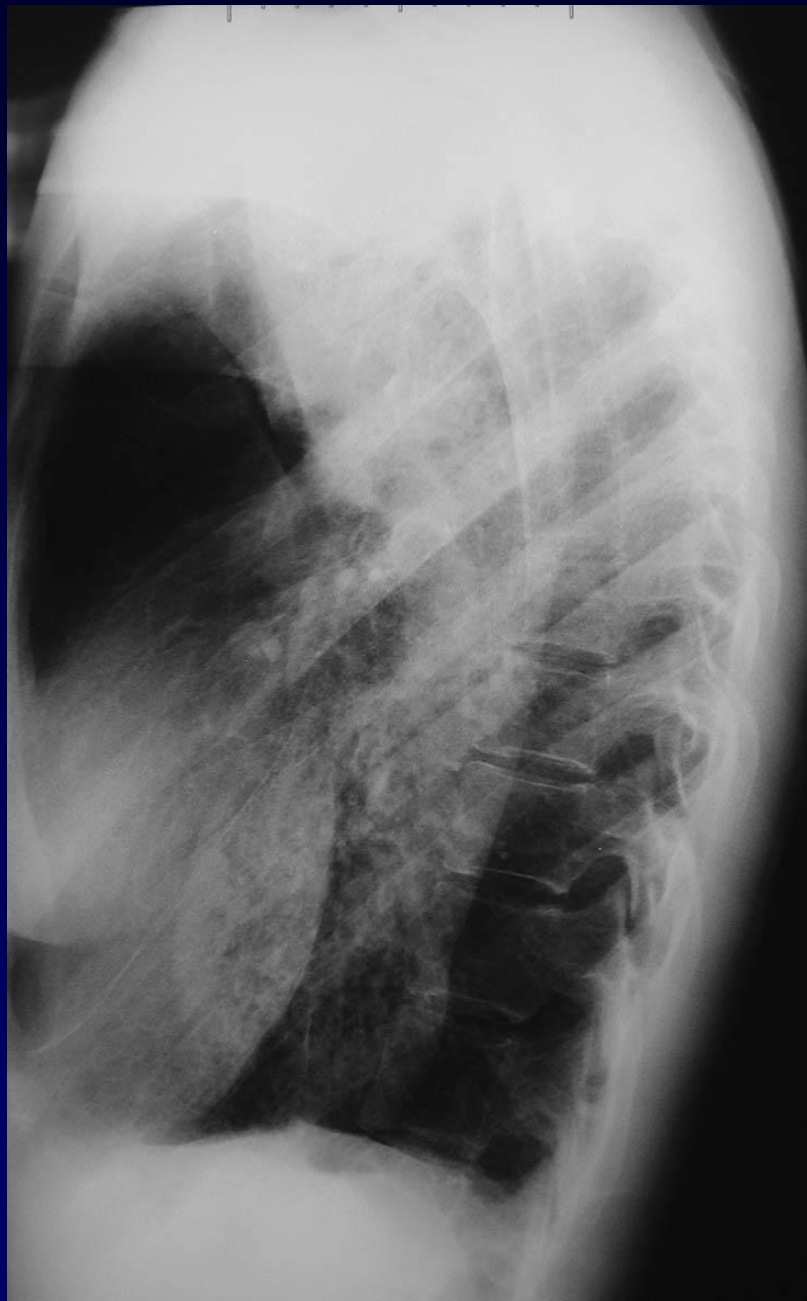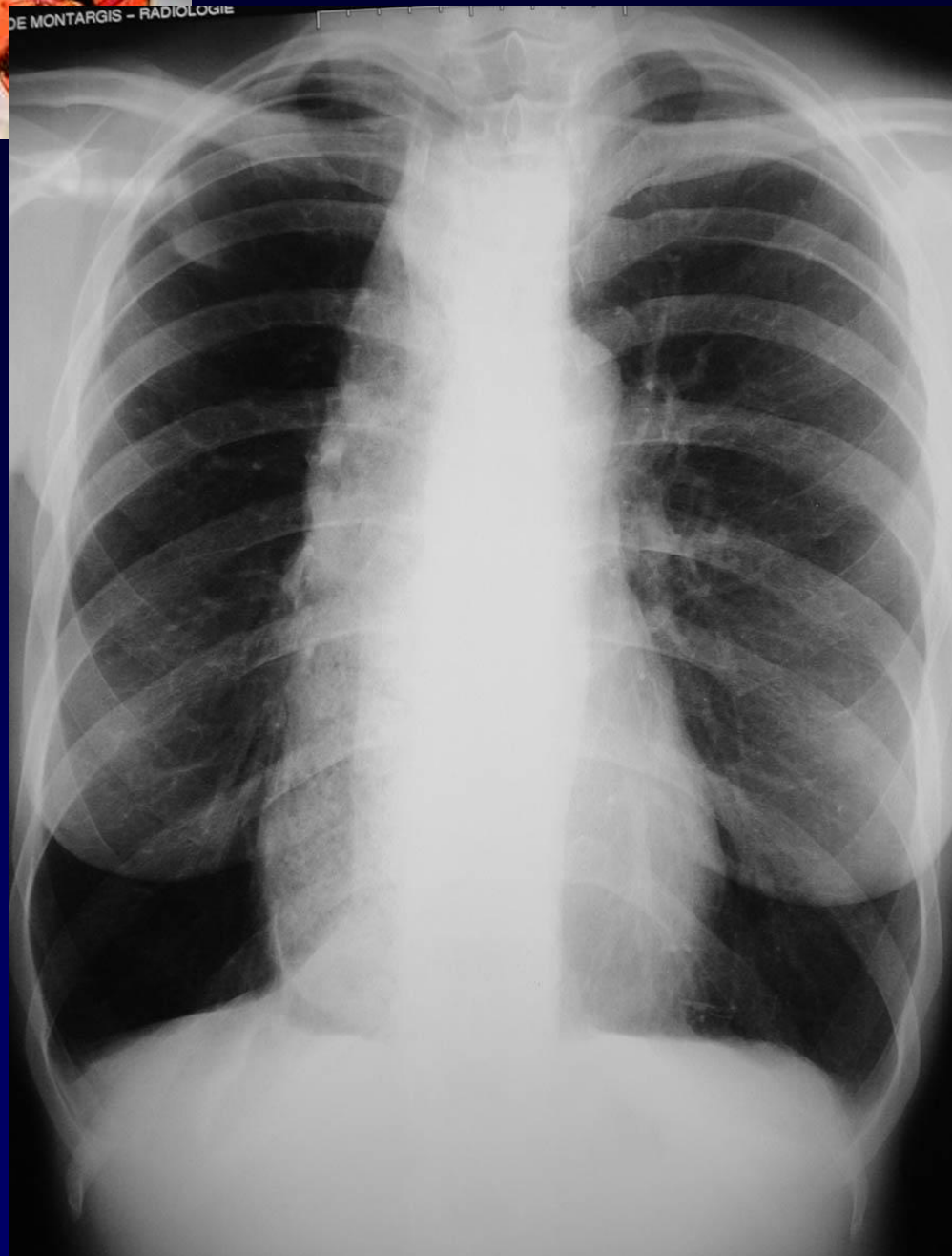




M EL HAJJAM

Femme de 41 ans

Dysphagie





Diagnostic ?



Méga-œsophage idiopathique